

## EVALUATION OF CLINICAL EFFECTIVENESS OF MODIFIED FIXED TWIN BLOCK APPLIANCE IN THE TREATMENT OF SKELETAL CLASS II MALOCCLUSION WITH VERTICAL GROWTH PATTERN

1. Dr. N. G. Toshniwal

Prof. & HOD

Dept. of Orthodontics and Dentofacial orthopaedics,

Rural Dental College,

Pravara Institute Of Medical Sciences,

Loni – 413736

Mob no. 9423523708

e-mail id – [drngtoshniwal@gmail.com](mailto:drngtoshniwal@gmail.com)

2. Dr. Uday Nandkishorji Soni

PG Student,

Dept. of Orthodontics and Dentofacial orthopaedics,

Rural Dental College,

Pravara Institute Of Medical Sciences,

Loni – 413736

Mob no. 9422647190

e-mail id – [udaysoni88@rediffmail.com](mailto:udaysoni88@rediffmail.com)

3. Dr. Ninad Gharat

PG Student,

Dept. of Orthodontics and Dentofacial orthopaedics,

Rural Dental College,

Pravara Institute Of Medical Sciences,

Loni – 413736

**Abstract:**

**Introduction:** The modified fixed twin block is an efficient, uncomplicated myofunctional appliance for the correction of skeletal class II malocclusion in late pubertal growth spurt in non-compliant patients.

**Aim:** To evaluate clinical effectiveness of modified fixed twin block appliance in treatment of skeletal class II malocclusion with vertical growth pattern patients.

**Material and methods:** Fifteen patients were chosen with skeletal class II malocclusion with mean age of 13 years 6 months. Average study period was twelve months. Cephalometric analysis and model analysis were carried out to evaluate skeletal and dental changes.

**Results:** Modified fixed twin block appliance contributes to correction of class II molar and canine relationship by both dentoalveolar and skeletal effects on both jaws in vertical growers.

**Conclusion:** Modified fixed twin block appliance is a logical choice in case of hyperdivergent patients for correction of skeletal class II malocclusion.

**INTRODUCTION**

The problem of vertical dimension is complex and multifactorial, arising from a discrepancy between mandibular ramus growth and tooth eruption. Vertical problem usually characterized by features like open bite, hyperdivergent face, maxillary alveolar hyperplasia, maxillary vertical excess.<sup>(1, 2, 3)</sup> Functional orthopedic treatment seeks to improve skeletal and dental relationship of the jaws, the challenging task is to correctly position jaws transversely, antero-posteriorly and vertically with correct overbite, overjet and centric relation. This can be done using myofunctional appliances, which require favourable growth, proper treatment planning and good patient cooperation.<sup>(4)</sup>

The goal of modified fixed twin block therapy was to maximize the growth response to functional mandibular protrusion by using an appliance system that is simple, comfortable and aesthetically acceptable to the patients.<sup>(5)</sup> Modification of twin block can be done by incorporating expansion screw for transverse correction and engaging vertical elastics to reduce excess posturing out of mandible and maintain effectiveness in correcting sagittal and vertical discrepancies. So the difficult approach of correcting malocclusion in three planes transverse, sagittal and vertical achieved by modified fixed twin block efficiently, effectively and rapidly.

**AIMS AND OBJECTIVES**

The main aim of this study was to evaluate the clinical efficacy of modified fixed twin block appliance in the treatment of skeletal Class II malocclusion with vertical growers in 3 dimensions.

Other objectives of current study was to evaluate the changes brought about by the modified fixed twin block appliance in horizontal and vertical direction, the soft tissue changes, the amount of overjet and overbite reduction, the correction of molar and canine relationship achieved during the first 6 months of treatment and also the compliance of patient with modified fixed twin block appliance.

## MATERIAL AND METHODS

Fifteen cases of skeletal class II malocclusion with dolicofacial facial type with convex facial profile were selected, all patients with mean age of 13.6 years (S.D.  $\pm$  1.4 years). Pre-treatment cephalometric analysis and functional analysis was done for each patient. Almost all cases were in the last phase of skeletal growth as evaluated with the help of cervical vertebra maturity index of Hassel and Farman (CVMI). All subjects were either in between CVMI stage 4 and CVMI stage 5. These two skeletal maturity indices were selected as they give the amount of potential percentage of growth completed or remained. Above two indicators showed that the subjects were in last phase of growth and about 20-25% of potential growth is remained.<sup>(6)</sup>

Records collected include detailed clinical history, diagnostic casts, lateral cephalogram before treatment and twelve months after removal of appliance and compared with standardized cephalometric norms.

### CONSTRUCTION OF MODIFIED FIXED TWIN BLOCK (fig. 1 a, b, c, d, e, f & g)

First step is bite registration<sup>(7)</sup>; the length of the patient's total protrusive path is determined by recording the overjet in centric occlusion and fully protrusive occlusion. The activation must not exceed 70% of the total protrusive path. Vertically the bite is activated on the incisors with 4 mm inter-incisal clearance, resulting in approximately 5 mm clearance between the cusps of the first premolars.

**The maxillary wire framework** mainly consisted of three components

- A) Two wire frameworks, extending from first premolar to first molar region, with hooks in canine regions on the buccal side, to engage vertical elastics.
- B) An expansion screw across the palate between first and second premolar.
- C) A labial bow extending from second premolar of one side to other side.

**The mandibular wire framework** mainly consisted of two wire components

- A) A labial bow with loops, made up of 19 gauge stainless steel wire up to the first bicuspid, extending distally through acrylic, modified into a hook near molar region. The hook can be used to engage elastics. The distal arm of U loop was again bending parallel to occlusal plane to provide short distal extension till the first bicuspid.

B) A lower lingual bar is constructed and closely adapted to the lingual surface of the anterior immediately above the cingulum of lower anterior teeth for vertical control of incisors. The labial bow soldered to buccal extensions of lingual arch at the premolar region.

The basic philosophy of upper and lower inclined occlusal blocks is same as for this modified version as that of removable twin block.<sup>(5)</sup> Bilateral lower inclined bite blocks were prepared first, and angulated from distal surface of second premolar at 70° to the occlusal plane. Buccolingually block covers the occlusal surface and also the buccal and lingual portion of tooth so as to give maximum rigidity to appliance. Acrylic blocks were prepared in cold cure.

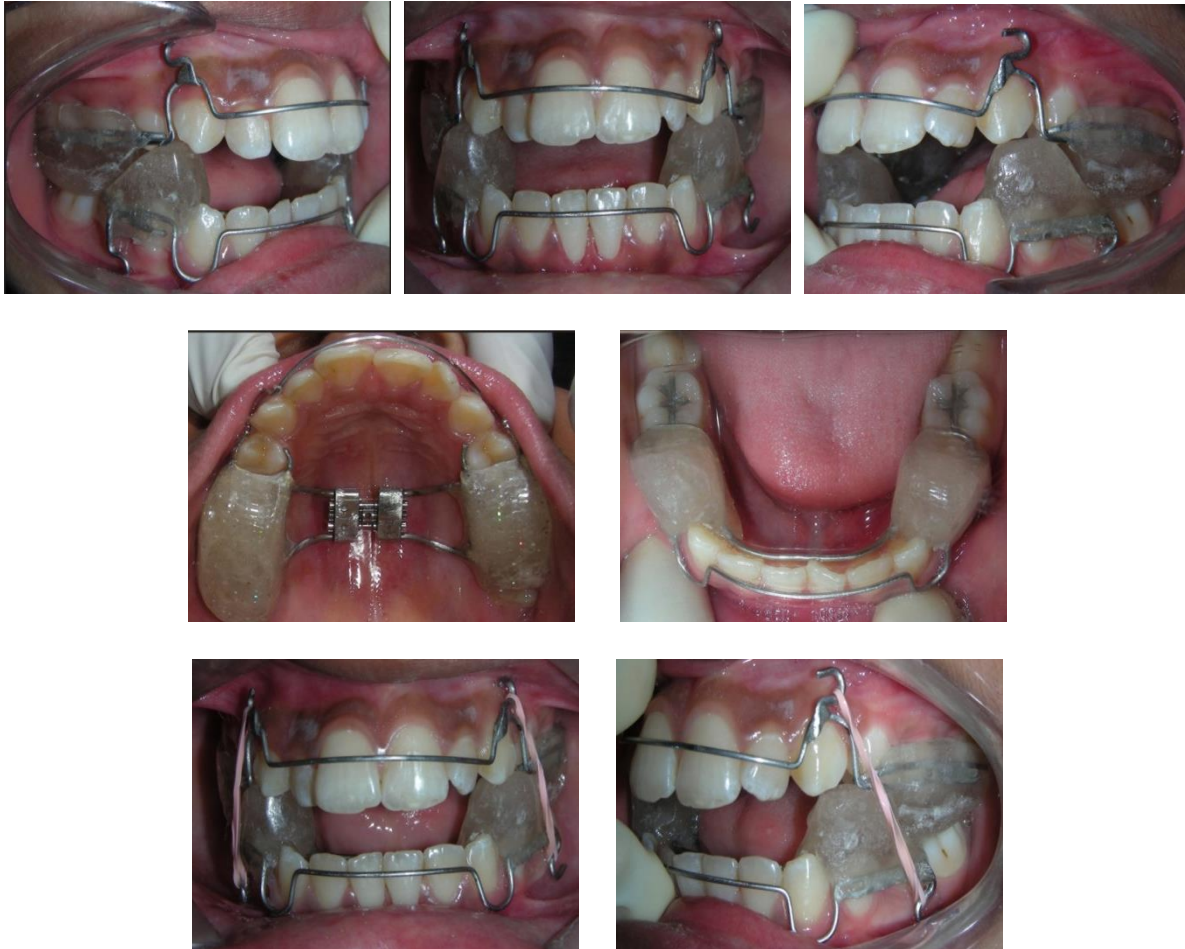


Fig. 1 (a, b, c, d, e, f & g) modified fixed twin block appliance

Before cementing the appliance proper scaling, polishing and fluoride application was done with low PH acidulated phosphate fluoride gel. The upper and lower twin blocks are cemented with Glass Ionomer Cement for luting as it has anticariogenic property in it.

The study was carried out for six months period. Appliance was removed to collect records required for study.

## CEPHALOMETRIC ANALYSIS

All the patients were exposed for lateral cephalometric radiograph in standing position on cephalometric X ray machine at a distance of 5 feet between the X-ray target and mid-sagittal plane of the head of the subject and the mid-sagittal plane - film distance was 15 cm. The x-ray machine settings were standardized at 78 KVP, 100 Ma and 2.8 sec exposure time. All the X ray films were exposed, developed and fixed under similar conditions to achieve uniformity of results. All tracings were carried out directly on the cephalogram manually by using matt lacquered polyester acetate paper under similar condition by a single individual to reduce systematic error of cephalometric measurement. The linear and angular measurements were made by using a set square and protractor with an accuracy of 0.5mm and 0.5° respectively.

## STUDY MODEL ANALYSIS

The study models were assessed for following changes before and after six months with Modified Twin Block Appliance. The linear changes were measured in molar relationship and canine relationship bilaterally with the help of digital vernier caliper.

## RESULTS

The statistical results obtained from cephalometric analysis are presented in the tables and linear changes in molar and canine relationship bilaterally with PRE-TREATMENT and POST-TREATMENT study models.

By applying Student's Unpaired 't' test, it was found that there is **no significant difference** in between mean values of overbite, incisor mandibular plane angle, articular angle, upper and lower gonial angle, GoGn-SN, SNA, Y axis, saddle angle, gonial angle, Jarabacks ratio, but there is **significant difference** in mean value of overjet, molar and canine relation on right and left side, SNB and ANB when compared with pre and POST-TREATMENT (table 1–6).

## DISCUSSION

Modified fixed twin block appliance brought expansion and stimulate overall amount of mandibular growth in appropriate direction, and restricts unfavorable maxillary growth. Fixed twin block brings mandible forward and reduction in overjet observed by 2.86 mm, few practical problems reported with this appliance posterior open bite which should be corrected with absolute intrusion.

The cephalometric analysis with this study evaluated treatment results of skeletal and dentoalveolar changes produced by fixed twin block appliance during twelve months of bonding period.

## ANTERO-POSTERIOR SKELETAL RELATIONSHIPS

The maxillary angle analogue SNA showed no significant reduction, this indicates during treatment reciprocal effect of protracting muscle restricts further maxillary growth and minimum distalization effect on maxilla.<sup>(8, 10)</sup>

Mandibular angle analogue SNB indicating forward mandibular jumping showed increase in angle by 3.03°. It seems possible that forward growth of mandible is due to glenoid fossa remodelling.

The mean difference of ANB pre and POST-TREATMENT was 3.06°.

Table . 1 CHANGE IN ANTEROPOSTERIOR SKELETAL MEASUREMENTS IN PATIENTS ( PRE-TREATMENT & POST-TREATMENT)

PARAMETERS	PRE TREATMENT MEAN+/-SD	POST-TREATMENT MEAN+/-SD	PAIRED t TEST VALUE	pVALUE	SIGNIFICANCE
SNA	80.93+/-0.79	80.87+/-0.83	0.20	p>0.05	NOT SIGNIFICANT
SNB	76.20+/-1.01	79.93+/-1.283	8.85	P<0.05	<b>SIGNIFICANT</b>
ANB	5.93+/-0.884	2.87+/-0.516	11.77	P<0.05	<b>SIGNIFICANT</b>

Table . 2 CHANGE IN MANDIBULAR LENGTH MEASUREMENTS IN PATIENTS (PRE-TREATMENT & POST-TREATMENT)

PARAMETERS	PRE TREATMENT MEAN+/-SD	POST-TREATMENT MEAN+/-SD	PAIRED t TEST VALUE	pVALUE	SIGNIFICANCE
Co-Go	57.53+/-1.807	59.05+/-2.609	1.54	P>0.05	NOT SIGNIFICANT
Co-Gn	76.20+/-1.01	79.93+/-1.283	1.18	P>0.05	NOT SIGNIFICANT
Go-Gn	5.93+/-0.884	2.87+/-0.516	1.02	P>0.05	NOT SIGNIFICANT

Table . 3 CHANGE IN MAXILLARY LENGTH MEASUREMENTS IN PATIENTS (PRE-TREATMENT & POST-TREATMENT)

PARAMETERS	PRE TREATMENT MEAN+/-SD	POST-TREATMENT MEAN+/-SD	PAIRED t TEST VALUE	pVALUE	SIGNIFICANCE
Pns-Point A	48.75+/-2.15	47.7+/-3.65	0.98	P>0.05	NOT SIGNIFICANT
Co-Point A	88.10+/-3.18	87.30+/-0.71	0.87	P>0.05	NOT SIGNIFICANT

Table . 4 CHANGE IN VERTICAL SKELETAL MEASUREMENTS IN PATIENTS (PRE-TREATMENT &amp; POST-TREATMENT)

PARAMETERS	PRE TREATMENT MEAN+/-SD	POST-TREATMENT MEAN+/-SD	PAIRED t TEST VALUE	pVALUE	SIGNIFICANCE
N-Me	113.76+/-6.02	118.81+/-6.78	1.87	P>0.05	NOT SIGNIFICANT
S-Go	70.92+/-4.72	76.37+/-4.66	1.91	P>0.05	NOT SIGNIFICANT
GoGn-SN ANGLE	35.13+/-3.067	34.16+/-4.334	1.43	P>0.05	NOT SIGNIFICANT

Table . 5 CHANGE IN DENTAL MEASUREMENTS IN PATIENTS (PRE-TREATMENT &amp; POST-TREATMENT)

PARAMETERS	PRE TREATMENT MEAN+/-SD	POST-TREATMENT MEAN+/-SD	PAIRED t TEST VALUE	pVALUE	SIGNIFICANCE
UPPER INCISOR- SN PLANE ANGLE	113.9+/-5.86	110.5+/-4.16	1.23	P>0.05	NOT SIGNIFICANT
UPPER INCISOR- N-POG LINE MM	7.80+/-1.73	5.80+/-1.75	1.76	P>0.05	NOT SIGNIFICANT
LOWER INCISOR- A-POG LINE MM	3.23+/-2.97	5.85+/-2.16	1.32	P>0.05	NOT SIGNIFICANT
LOWER INCISOR-MANDIBULAR PLANE ANGLE	92.40+/-2.97	95.27+/-3.05	1.07	P>0.05	NOT SIGNIFICANT
INCISOR OVERJET	5.833+/-0.5563	2.966+/-0.9155	10.38	P<0.05	<b>SIGNIFICANT</b>

Table . 6 CHANGE IN CRANIAL BASE MEASUREMENTS IN PATIENTS (PRE-TREATMENT &amp; POST-TREATMENT)



PARAMETERS	PRE TREATMENT MEAN+/-SD	POST-TREATMENT MEAN+/-SD	PAIRED t TEST VALUE	pVALUE	SIGNIFICANCE
SADDLE ANGLE	127.53+/-3.219	126.39+/-3.44	1.28	P>0.05	NOT SIGNIFICANT
ARTICULAR ANGLE	145.93+/-3.868	144.76+/-3.677	1.87	P>0.05	NOT SIGNIFICANT
GONIAL ANGLE	131.33+/-1.759	130.2+/-4.699	1.01	P>0.05	NOT SIGNIFICANT

### Mandibular length measurements

The mean difference in pre and post-treatment values for mandibular unit length (Co-Gn) – 2.21mm, mandibular body length (Go-Gn) – 2.5 mm and ramus height (Co-Go) – 1.52 mm. These values were statistically **not significant**. The changes in the skeletal base were mainly due to increase in angle SNB which was statistically highly significant.

### Maxillary length measurements

The mean differences in pre and post-treatment values for respective measurement were maxillary unit length – 0.8 mm. change in SNA angle was not statistically significant. No such restrictive effect on maxilla was seen.

### vertical skeletal measurements

Results of the study showed though there was change in gonial angle, articular angle, mandibular plane angle and increase in anterior facial height and posterior facial height but not significant. Jarabacks ratio was maintained throughout treatment. Intrusive force of bite blocks brought about an intrusion of the maxillary and mandibular posterior teeth but not significantly. [9]

### Dental measurements

Upper incisor to SN plane angle is reduced with respect to SN plane. Linear distance from upper incisor to N-Pg line is also reduced but the change is not significant.

Linear distance from lower incisor to A – Pog line and also incisor mandibular plane angle increased.

The intrusive force of the bite blocks brought about an intrusion of the maxillary and the mandibular posterior teeth but change in mean value is not significant.



### **Incisor & molar overjet**

Mean values of incisor and molar overjet are 2.86 mm and 4 mm respectively. Both incisor and molar overjet are statistically significant.

### **CLINICAL EFFICIENCY**

After evaluation it can be concluded that, there was expansion in maxillary arch, decrease in angle ANB is mainly due to forward positioning of mandibular base, inhibition of forward growth of maxilla and minimum increase in inclination of lower incisors.

Generally forward positioning force to mandible is transmitted to maxilla and upper anterior as the restrictive force. Reduction in overjet should be mainly due to advancement of mandible and neither due to increase in inclination of lower incisors nor due to reduction in inclination of upper incisor.

Vertical growers tend to have weak musculature<sup>(11,12)</sup>; removable twin blocks are prone to posture out of appliance which reduces the effectiveness in correcting both sagittal and vertical discrepancies. Vertical elastics can help to overcome this problem. But if vertical elastics are used with removable twin block, the appliance won't retain in the oral cavity. Hence this problem of retention can be overcome by use of fixed twin block.

Drooping of the mandible, dislodgement of appliance was not seen with fixed twin block appliance. Continuous forces are applied hence chances of more effective intrusion of posteriors.

With the elimination of pre-functional therapy maximum benefit can be achieved to correct mandible sagittally, when minimum growth is remained with a great range of jaw movement. Problem of narrow maxillary arch can be solved by rapid palatal expansion with modified Haas expander if inter-maxillary suture is not fused.

As it is tooth borne appliance so chances of dento-alveolar changes are more. It can be used only in early permanent dentition with well aligned arches.

### **CONCLUSION**

Modified fixed twin block brought about expansion of maxillary arch and contributes to correction of class II molar relationship by differential dentoalveolar and skeletal effects on both jaws. Improvement of relationship between maxillary and mandibular skeletal bases and occlusion from class II molar and canine relationship to class I relationship.

Cephalometric findings conclude that promoted growth of lower jaw and restricted growth of upper jaw. All our hyperdivergent class II patients maintained in vertical dimensions throughout treatment. Modified fixed twin block could be a logical choice in cases of vertical growers as continuous force is applied by vertical elastics on the maxillary and mandibular posterior segment and also accelerates correction of distal occlusion.

### **REFERENCES**

1. McNamara JA Jr. Components of class II malocclusion in children in 8-10 years of age 1981; 51:177-202

2. Moschos A Papaopolous: Orthodontic treatment of class II non compliant; Current principal and techniques Mosby 2006
3. Pearson LE. The management of vertical dimension problem in growing patients, from Enigma of vertical dimension. InMcNamaraJA Jr.(ed): craniofacial growth series 36, centre for Human Growth and Development Ann Arbor MI , the university of Michigan 2000.
4. Bjork A: Prediction of mandibular growth rotation AJODO 1969; 55: 585-599
5. William J Clark; Twin block functional therapy; Mosby 1995.
6. Hassel and Farman; Skeletal maturation evaluation: AJODO; 1987: 58-66
7. Ovain H. Malik, Michael J.F. Read A Chipron fixed functional appliance : Journal of clinical orthodontics 2006
8. Michael J.F. Read. The integration of functional an fixed appliance treatment Journal of Orthoontics 2001; (28): 13-18
9. Vaden JL, Pearson LE Diagnosis of vertical dimension, seminar in orthodontics 2002; 8(3):120-129.
10. Schudy FF Vertical growth versus anteroposterior growth as related to function and treatment Angle orthodontics 1964; 34: 75-93
11. Nahoum anterior open bite: a cephalometric analysis and suggested treatment procedures AJODO 1975; 67: 513-520.
12. Nanda SK Patterns of vertical growth in the face AJODO 1988; 93: 103-116.