

SURGICAL EXPOSURE OF IMPACTED MAXILLARY CANINE AS AN ADJUNCT TO ORTHODONTIC TREATMENT: CASE REPORT

Kirtika,¹ Singh Pardeep,² Attresh Gyanander³

1. M.D.S, Periodontics

2. M.D.S, Prosthodontics

3. M.D.S, Oral and maxillofacial surgery

Author's address-

1. H No. D3/10, Ardee City, Sector 52, Gurugram, India-122003

Email id- kirtikasheoran@gmail.com, 8950416042

2. H No. D3/10, Ardee City, Sector 52, Gurugram, India-122003

Email id- pradeepsheokand7@gmail.com, 8221879877

3. H No-1114, Sector 2, Faridabad, Haryana ,india-121004

Email id- drgyananderattresh@gmail.com, 8901521591

ABSTRACT: *Disturbances in the eruption of permanent maxillary canines are common because they develop deep within the maxilla and have the longest path to travel compared with any other tooth in the oral cavity. The maxillary canine is second only to the mandibular third molars in frequency of impaction. The impacted canine has always implied a difficult therapeutical management for the clinician. The therapy of this condition can be considered successful only if the forced eruption and the subsequent alignment lead the tooth to a stable position in the dental arch along with the presence of a healthy periodontium*

Keywords: *impacted tooth, closed eruption, periodontal surgery, buccally impacted*

INTRODUCTION: Canines play a vital role in facial appearance, dental esthetics, arch development and functional occlusion. As a result, orthodontists have acknowledged the significance of retaining impacted maxillary canines and periodontists have proposed various techniques to effectively and efficiently recover these teeth. In dentistry, canine impaction is a dental anomaly that occurs frequently and clinicians must be prepared to manage it. The maxillary and mandibular third molars are the most commonly impacted teeth due to their long development time.¹ The maxillary cuspid is the second most frequently impacted tooth (2%)².

Etiologic factors associated with impacted canines.

LOCALIZED

Tooth size–arch length discrepancies
Failure of the primary canine root to resorb
Prolonged retention or early loss of the primary canine
Ankylosis of the permanent canine
Cyst or neoplasm
Dilaceration of the root
Absence of the maxillary lateral incisor
Variation in root size of the lateral incisor (that is, peg-shaped lateral incisor)
Variation in timing of lateral incisor root formation
Iatrogenic factors
Idiopathic factors

SYSTEMIC

Endocrine deficiencies
Febrile diseases
Irradiation

GENETIC

Heredity
Malposed tooth germ
Presence of an alveolar cleft

SEQUELAE OF MAXILLARY CANINE IMPACTION¹

Sequelae of abnormal eruption paths within the dentoalveolar process can include impactions and have serious clinical ramifications. For example, labially or palatally impacted teeth cause migration of the neighboring teeth and loss of arch length. In addition, unerupted canines may increase the patient's risk of developing a cystic lesion and infection and cause root resorption of

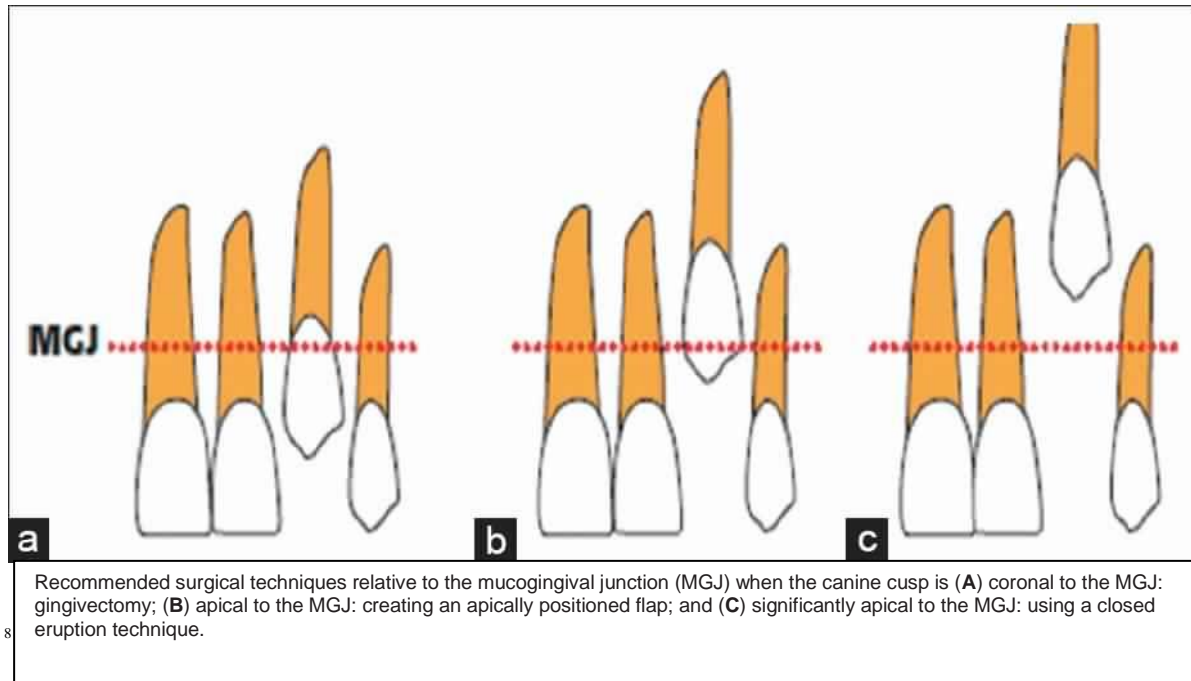
the nearby lateral incisors and jeopardize the longevity of lateral incisors.³ Lateral incisors adjacent to ectopically erupted canines have an incisor root resorption incidence of approximately 0.7 percent, but even with continued root development, an abnormally erupting canine can harm the adjacent lateral incisor.³⁻⁵

Well managed surgical technique and orthodontic treatment permit the traction of impacted canines to the centre of crest, thus simulating a physiological eruption pattern. Treatment of impacted teeth requires a combination of orthodontics and surgery, both of which might cause damage to the teeth and the supporting structures.

Surgical technique for exposing impacted canine¹²

IMPACTION SITE	EXPOSURE TECHNIQUE	INDICATION THAT SURGICAL TECHNIQUE NEEDED TO BE PERFORMED	INITIATION OF ORTHODONTIC THERAPY	ADVANTAGES OF USING THE TECHNIQUE	DISADVANTAGES OF USING THE TECHNIQUE
Labial	Gingivectomy	Canine cusp is coronal to mucogingival junction (MGJ); adequate amount of keratinized gingiva is present; canine is not covered by bone	Orthodontic traction usually is not necessary because the tooth tends to erupt normally (usually only leveling and alignment is adequate)	Easy to perform; less Traumatic	Used only occasionally; loss of attached gingiva, possible damage to periodontium; potential gingival overgrowth at surgical site
	Apically positioned flap	Canine crown is apical to MGJ; the amount of attached gingiva is minimal (used when less than 3 millimeters of attached gingiva is present)	Two to three weeks after surgery	Commonly used; conservation of keratinized gingiva	Increased risk of experiencing gingival recession; height differences and orthodontic relapse; more traumatic
	Closed eruption	Tooth is in the center of alveolus; crown is significantly apical to MGJ	One to two weeks after surgery	Greater esthetics; ease of tooth movement	Patient discomfort; second surgery may be necessary; possible mucogingival problems

Palatal	Closed flap	Canine is located near the lateral and central incisors, horizontally positioned, and higher in the roof of the mouth	One to two weeks After surgery	Immediate orthodontic traction	Bone necrosis; root resorption; longer operation time; repeat surgeries as a result of failure to erupt, bond failure due to blood or saliva contamination and fractured wire ligature; slightly longer overall treatment time
	Open eruption	Late mixed dentition; permanent dentition	When cusp tip is at the level of the occlusal plane	Improved bone levels; little or no root resorption; fewer reexposures; shorter overall treatment time; less operating time; improved oral hygiene during treatment	Failure to erupt may extend total treatment time; unable to influence the path of eruption
	Open window Eruption	Canine is located near the lateral and central incisors, horizontally positioned, and higher in the roof of the mouth	One to two weeks after removal of the pack	Visualization of the crown and better control of the direction of tooth movement; avoidance of moving the impacted tooth into the roots of the adjacent teeth	Gingival overgrowth at incision site; gingiva is subject to infection; patient discomfort
	Tunnel traction *	The presence of primary canine in the arch	The suture is removed 10 days after surgery and the traction phase begins	Reduced amount of bone around the impacted tooth; the permanent canine is guided into the primary canine socket site	Requires the presence of a primary canine



Localization and determination of a tooth's exact position is the foremost step in surgical exposure of an impacted tooth. This can often be done by palpation in labial impactions. However, the use of periapical radiographs and occlusal radiographs plays a major role in palatal and middle alveolar impactions.

An adequate amount of keratinized gingival tissue that is under proper plaque control, is a fundamental requirement for periodontal health.⁶ When teeth erupt unevenly in the center of the alveolar ridge, an adequate amount of keratinized tissue will surround the erupted permanent tooth. Labially or buccally erupting teeth show reduced dimensions of gingiva as abnormal eruption of permanent teeth restricts or eliminates the keratinized tissue between the erupting cusp and the deciduous tooth.⁷ A lack of attached gingiva poses a potential risk for gingival recession in labially or buccally erupted teeth due to the possibility of accumulation of plaque and/or traumatic tooth-brushing during subsequent orthodontic treatment.⁸ A good understanding between the orthodontist and the periodontist along with proper management of periodontal tissues can prevent these problems. In this paper, a case report is presented to discuss the validity of utilizing periodontal surgery to erupt impacted canine with maintenance of periodontal tissue around erupted canine.

Case report:

a 22 year old female undergoing orthodontic treatment reported to department of Periodontics for exposure of impacted maxillary canine .Patient was systemically healthy, in CBCT and On palpation, the tooth showed an erupting position that was facial to the crest of the alveolar process and entirely within the alveolar mucosa.(FIGURE 1)

Procedure(Closed Eruption Surgical Technique)

A horizontal crestal incision extending mesiodistally was given with 15 no blade.(FIGURE 2) Full thickness mucoperiosteal flap was raised with periosteal elevator. Once the flap was raised, a small portion of cortical bone, if present, was gently removed by means of a low-speed bur and the follicular socket was eliminated using a periodontal curette.(FIGURE 3) The impacted canine cusp tip was exposed and the enamel was dried with gentle suction and a dry gauge; a fine mesh was bonded as closely as possible to the cusp of the impacted canine. The bonding agent was light cured for 60 s. A handmade wire chain of rings approximately 1.5mm in diameter was prepared with a ligature wire and fixed to the fine mesh.(FIGURE 4) The flap was then repositioned and sutured into its original site with interrupted silk sutures. The chain emerged from the gingival tissue at the incision made in the middle of the alveolar ridge. Only enough bone is removed to place an orthodontic attachment on the tooth. After placemen of orthodontic attachment and ligature wire, flap was repositioned to its original site with the help of sutures.(FIGURE 5)

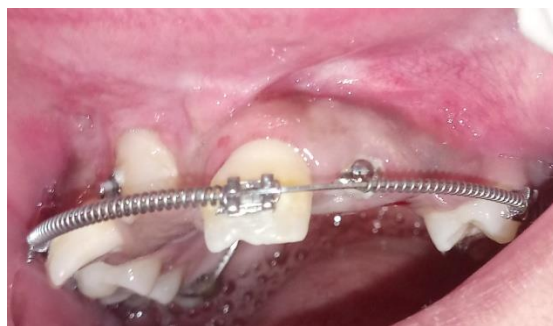

FIGURE 1

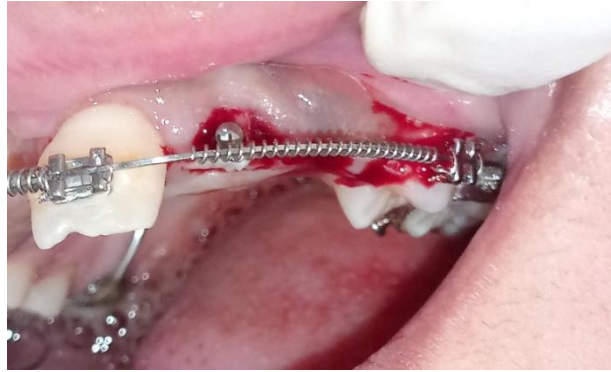

FIGURE 2

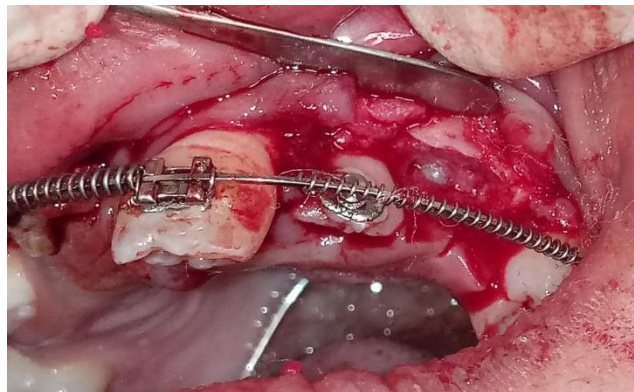


FIGURE 3

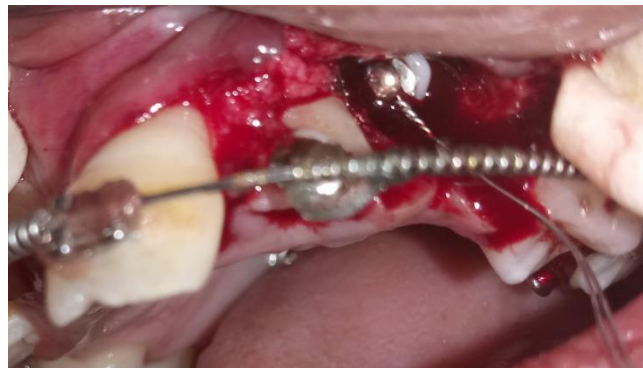

FIGURE 4

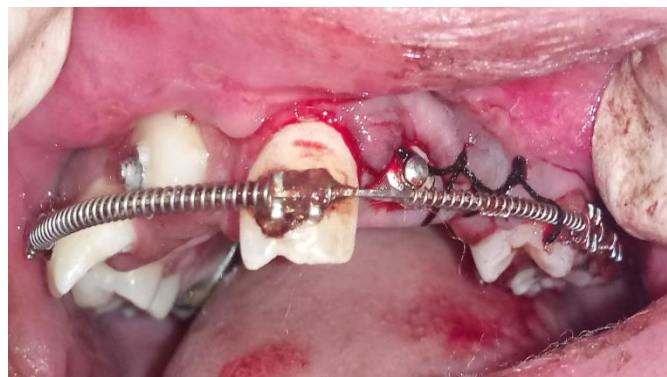

FIGURE 5

The patient was given oral hygiene instructions that included chlorhexidine rinsing of the mouth for seven days, but no tooth- brushing. One week later, sutures were removed and the area evaluated. Clinical examination revealed a favorable response in the absence of bleeding and inflammation. Mechanical tooth-brushing was reinstated one week after the surgery.

Discussion:

The management of impacted canines requires a demanding multidisciplinary approach. The treatment of impacted, ectopic or malpositioned maxillary canines is accomplished when the tooth has reached a proper alignment on the dental arch, with an adequate attached gingiva, and when there is no periodontal damage such as pockets the surgical– orthodontic treatment of an impacted tooth should simulate the physiological eruption pattern as much as possible aim of orthodontic therapy is to guide tooth eruption to the centre of the alveolar ridge, whereas periodontal–surgical management must guarantee the respect of the gingival tissues to avoid severe periodontal damage at the end of treatment. In the above case, a full-thickness flap was raised, allowing for minimal exposition of the impacted tooth. Paramarginal incisions of the flap were always made in order to avoid damage to the gingival margin and to the connective tissue attachment of the adjacent teeth. Delicate elevation of such flaps allowed for reducing surgical bleeding, which facilitated the placement of the attaching device and permitted to eliminate only a minimal amount of cortical bone and pericoronal tissues at the cusp of the impacted canine. The minimal bone removal has been stressed by several authors in fact, extensive bone removal around the impacted tooth’s crown to facilitate tooth eruption is considered too risky ^{9,10}. In addition, this type of access makes it possible to avoid dangerous involvement of the CEJ and of the root of the impacted tooth during the placement of the attaching device as well as to avoid exposure of the roots of the adjacent teeth. Finally, the repositioned flap maintains the entire amount of keratinized tissue and reduces discomfort during healing. Traction through this tunnel follows an eruption path that closely simulates the physiological one. Direct bonding and closed eruption technique reduced morbidity by minimizing wound size and reduced tissue overgrowth and additional surgeries by having a bracket placed at the time of exposure. When the tooth remains uncovered and is not covered by soft tissue, more rapid repositioning occurs and treatment time is decreased The surgical caveat is that the cemento-enamel junction of the

impacted tooth not be exposed. Exposure of the cemento- enamel junction has shown to cause excessive loss of alveolar supporting bone. Study by Lang and Loe (1972) demonstrated that although tooth surfaces may be kept free of clinically detectable plaque, areas with less than two millimeters of keratinized gingiva tend to remain inflamed. The study proposed that a movable gingival margin would facilitate the introduction of microorganisms into the gingival crevice, resulting in a thin subgingival bacterial plaque that would be difficult to detect and not easily removed by conventional tooth-brushing¹¹. A gingivectomy procedure could lead to removal of all the attached gingiva for the canine, and result in an alveolar mucosal attachment. An adequate band of attached gingiva can be achieved by either apically repositioning a flap with attached gingiva, or by grafting keratinized gingiva from the palate to the site of exposure. This case report shows the use of a surgical procedure for uncovering impacted canine, which when used judiciously, gives excellent results and helps in preventing future mucogingival problems. Future studies are required to evaluate the long-term efficiency of such procedures.

Conclusion:

This treatment demonstrates a more predictable outcome than attempting to cover up any root surface exposure that may develop later. Finally, the importance of allowing the patient to understand the potential defect and its outcome and the options to choose whether or not to receive prophylactic treatment, is clearly the main issue of professional dedication to the patient. This case report shows that the mucogingival interceptive surgeries, when used judiciously and at appropriate times, can be helpful in preventing future mucogingival problems. This requires a coordinated approach on the part of both the periodontist and the orthodontist, which would ultimately benefit the patient in maintaining a trouble-free periodontium.

References

- 1 *Fastlicht S. Treatment of impacted canines. Am J Orthod 1959;40:891*
- 2 *Bass T. Observations on the misplaced upper canine tooth. Dental Practitioner 1967;18:25-34*
- 3 *Ericson S, Kurol J. Resorption of maxillary lateral incisors caused by ectopic eruption of the canines: a clinical and radiographic analysis of predisposing factors. Am J Orthod Dentofacial Orthop 1988;94(6):503-513.*

- 4 . Power SM, Short MB. An investigation into the response of palatally displaced canines to the removal of deciduous canines and an assessment of factors contributing to favorable eruption. *Br J Orthod* 1993;20(3):217-223.
- 5 . Rimes RJ, Mitchell CN, Willmot DR. Maxillary incisor root resorption in relation to the ectopic canine: a review of 26 patients. *Eur J Orthod* 1997;19(1):79-84.
- 6 Pini Prato G, Baccetti T, Magnani C, Agudio G, Cortellini P. Mucogingival interceptive surgery of buccally-erupted premolars in patients scheduled for orthodontic treatment. I. A 7- year longitudinal study. *J Periodontol* 2000;71:172-81
- 7 Pini Prato G, Baccetti T, Giorgetti R, Agudio G, Cortellini P. Mucogingival interceptive surgery of buccally-erupted premolars in patients scheduled for orthodontic treatment. H. surgically treated versus nonsurgically treated cases, *J Periodontol* 2000;71:182-7
- 8 Agudio G, Prato GP, de Paoli S, Nevins M. Mucogingival interceptive surgery. *Int J Periodontics Restorative Dent* 1985;5:49-9
- 9 Kohavi, D., Becker, A. & Zilberman, Y. Surgical exposure, orthodontic movement, and final tooth position as factors in periodontal breakdown of treated palatally impacted canines. *American J Orthod* 1984a; 85:72–77.
- 10 Kokich, V. G. & Mathews, D. P. Surgical and orthodontic management of impacted teeth. *The Dental Clinics of North America* 1993; 37: 181–204.
- 11 Lang NP, Löe H. The relationship between the width of keratinized gingiva and gingival health. *J Periodont* 1972;43:623-7.
- 12 Marisela M, Bedoya, Jae Hyun Park. A review of the diagnosis and management of impacted maxillary canines. *JADA* 2009;140(12):1485-1493.